

Conservative dentistry

LEC: 5

Dr. Zanbaq

Cl II amalgam restoration

Preparations involving the proximal surfaces of posterior teeth are termed *Class II.*, the following surfaces are involved:

- Two surface cavity for posterior teeth fig 1A
- Three surface cavity for posterior teeth fig 1B
- Four surface (or more) cavity for posterior teeth fig 1C.

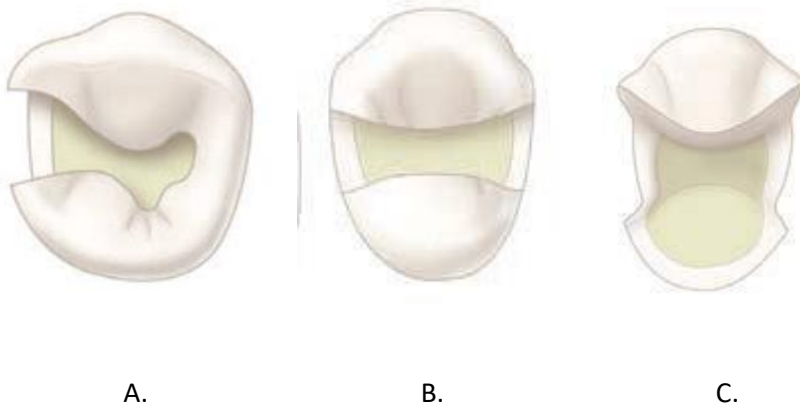


Fig 1: A: two surface cavity, B: three surface cavity, C: four surface cavity

Step 1: Outline Form and Initial Depth:

Establishing the outline form means placing the preparation margins in the positions they will occupy in the final preparation, the typical features of establishing proper outline form and initial depth are:

- Width of the facio-lingual walls of the cavity should be $\frac{1}{4}$ I.C.D.
- Preserving marginal ridge strength (2mm thickness marginal ridge).
- The depth of the preparation into dentin should be 1.5-2mm.

- The extent of the caries lesion affects the outline form of the proposed tooth preparation because the **objective is to extend to sound tooth structure also** Ideal outline includes all pits & fissures even if its sound to prevent them from caries in the future (**extension for prevention**).

Step 2: resistance form:

May be defined as the shape of the cavity that prevent fracture of the remaining tooth structure and the restoration this includes:

Factors prevent fracture of the tooth

- The facio-lingual width of the preparation should not exceed $\frac{1}{4}$ I.C.D (intercuspal distance).

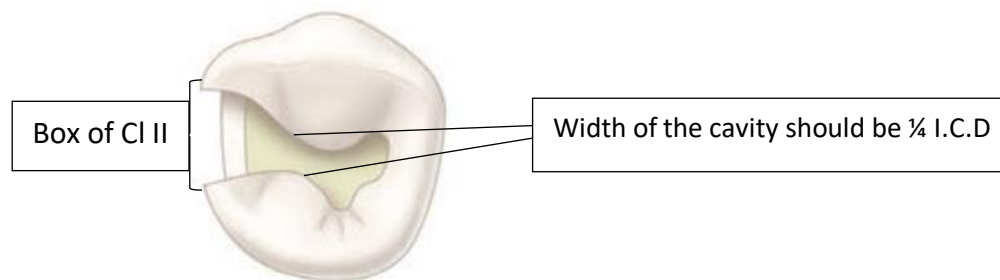


Fig2: CI II cavity preparation occlusal view

- Removal of unsupported enamel by making the margin (90° - 110°) because less than 90° the tooth is more subjected to fracture fig 3.
- Smooth pulpal floor & gingival seat to prevent stress concentration area.

- Mesial & distal walls of the cavity should be parallel and slightly diverge occlusally to be within the enamel rod direction and prevent any unsupported enamel at the marginal ridge.
- All internal line angle should be rounded to prevent stress concentration area fig3.
- Box shape of C1 II fig 2.
- Rounded gingival cavo-surface line angle

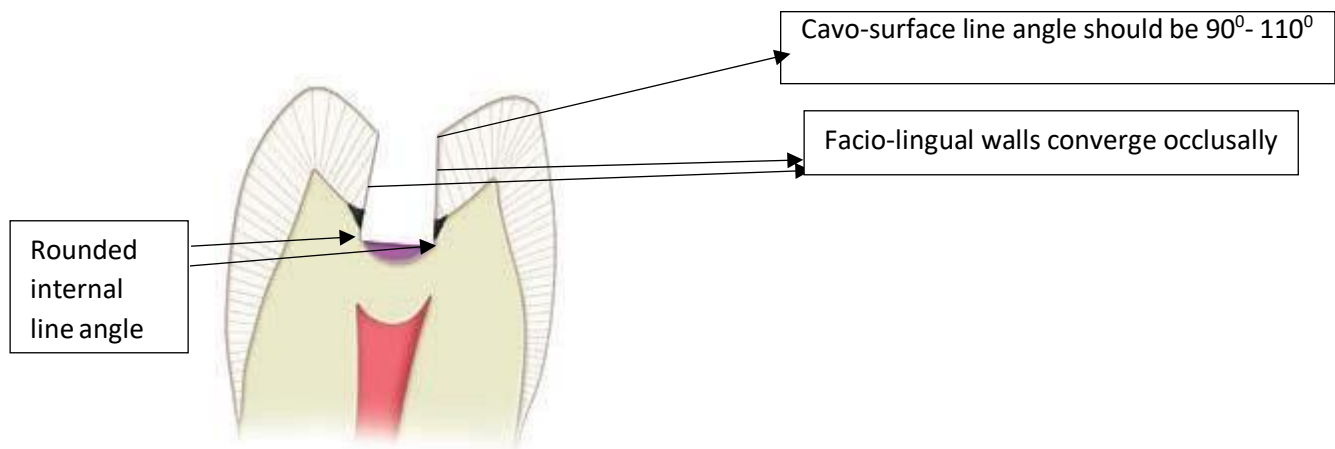


Fig 3: resistance factors which prevent fracture of the tooth

Preventing fracture of restoration

- The margins or Cavosurface line angle should be (90°-110°) if more than this lead to fracture of restoration.
- Facio-lingual width should be $\frac{1}{4}$ I.C.D because large surface area exposed to more force and fracture occur.
- Occlusal amalgam should have thickness of (1.5-2.0 mm) to resist fracture during function.

- The pulpal floor & gingival seat should be smooth to prevent concentration area on restoration.
- Rounded axio-pulpal line angle.

Step3. Retention form: is the shape of the cavity that permits the restoration to resist displacement through the tipping or lifting force.

To provide retention the cavity have the following:

- Facial & lingual walls should be parallel to each other or converge occlusally (5°) fig3.
- Pulpal floor & gingival seat of the cavity should be flat.
- Dove-tail preparation to increase retention fig4.
- Width of the cavity.
- The occlusal convergence of the box (from proximal view) fig5.
- Retentive grooves or locks in the axiofacial and axiolingual line angle fig5.

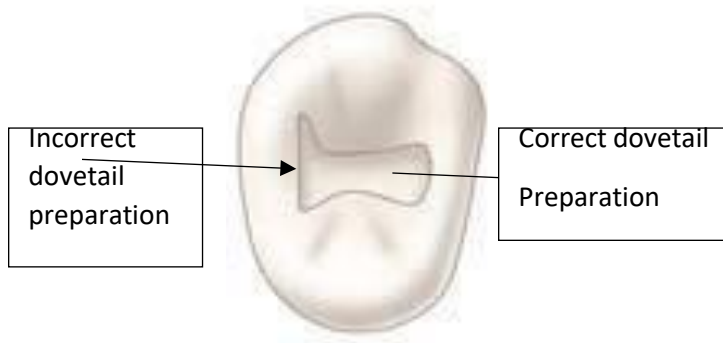


Fig: 4 dovetail

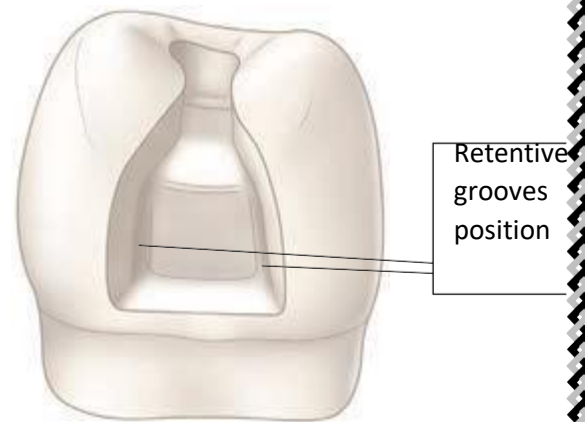


fig 5: proximal view of CIII box

Step 4: Convenience Form:

Convenience form is the shape or form of the preparation that provides for adequate observation, accessibility, and ease of operation in preparing and restoring the tooth.

Step5: Removal of remaining caries

Deep dentinal caries can be removed by using spoon excavator or large round bur with slow speed hand piece.

Step6: Finishing enamel walls

Involve making the wall smooth and removing of unsupported enamel.

Step7: Clean the preparation:

Removal of all debris by washing the cavity and drying it.

Clinically:

Occlusal outline form (occlusal step):

The occlusal outline form of Cl II tooth preparation for amalgam is similar to that for Cl I tooth preparation, enter the pit nearest the involved proximal surface with a punch cut using no.245 bur fig 6 A, the long axis of the bur & the long axis of tooth crown should remain parallel during cutting procedures, the bur should be rotating when applied to the tooth and should not stop rotating until removed.

Proper depth of the initial entry cut is 1.5-2 mm.

While maintaining the same depth & bur orientation move the bur to extend the outline to include the central groove & the opposite pit fig

6 B which provided by dovetail retention form the isthmus width should be as narrow as possible & no wider than $\frac{1}{4}$ I.C.D, it may be necessary to tilt the bur to create facial, lingual slight occlusal convergence & mesial and distal walls to diverge occlusally.

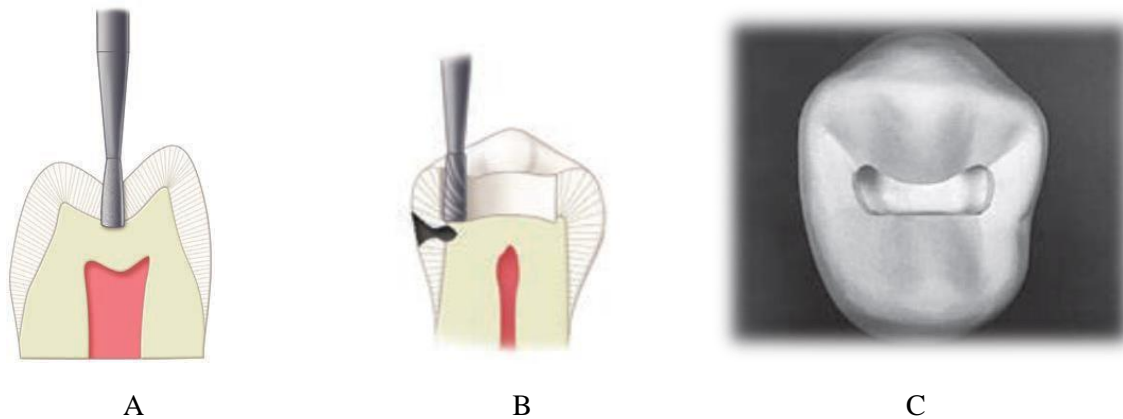


Fig6: A. initial depth, B. bur position to begin the proximal ditch cut. C, C I I cavity preparation

Proximal outline form (proximal box) preparation:

The objectives for extension of proximal margins are to:

- Include all caries, faults or existing restorative material.
- Remove unsupported enamel.
- Establish not more than 0.5 mm clearance with the adjacent proximal surface facially, lingually & gingivally.

The initial procedure in preparing the outline form of the proximal box is the isolation of the proximal enamel by the proximal **ditch cut** fig 7A this is a very important procedure in conservative tooth preparation.

Place the bur over the DEJ in the pulpal floor near the remaining marginal ridge, allow the end of the bur to cut the ditch gingivally then move the bur facially & lingually along the DEJ this lead to create **axial wall** fig 7 B, the ditch should extended gingivally just beyond the caries or

the proximal contact area, the location of final proximal margins (facial, lingual, gingival) should be established with hand instruments (chisel, hatchets, gingival margin trimmers) then remove the weakened enamel along the gingival wall by using the gingival margin trimmer in scraping motion.

Ideally the minimal clearance of the completed gingival margin with the adjacent tooth is 0.5 mm fig 7C.

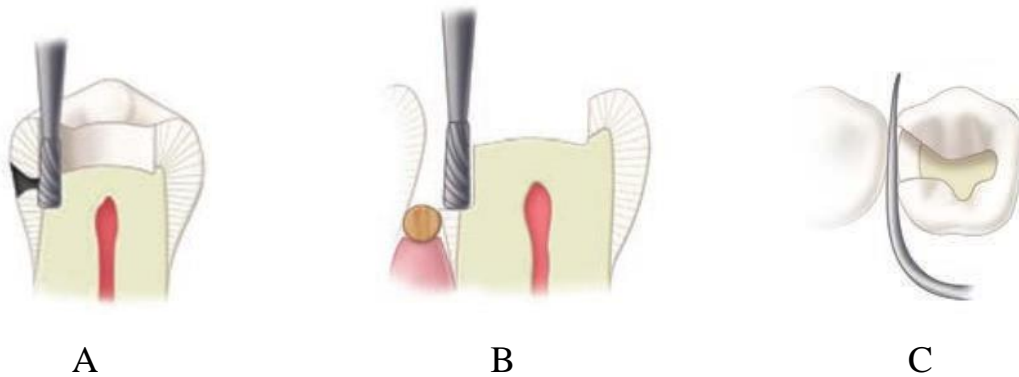


Fig 7: A. The proximal ditch is extended gingivally to the desired level of the gingival wall (i.e., floor). B, box formation. C, clearance of the gingival wall with the adjacent teeth.

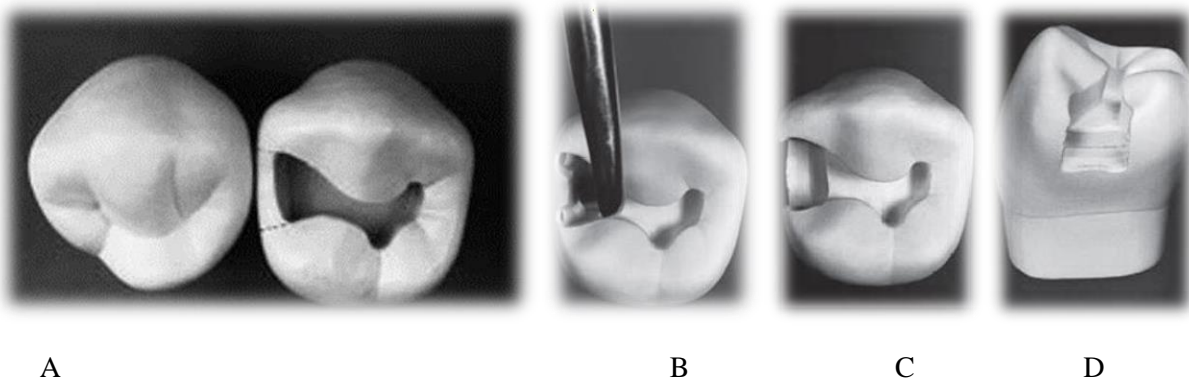


Fig 8: A. The proximal ditch is extended gingivally to the desired level of the gingival wall (i.e., floor). B, box formation. C, clearance of the gingival wall with the adjacent teeth D, proximal view of the tooth.

FINISHED

